

# Management of Scar Tissue

**Kim Rock Stockheimer**

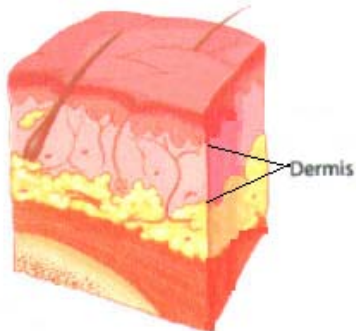
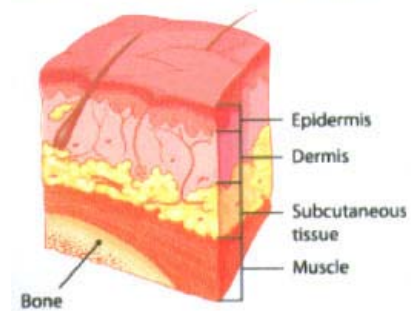
University of Wisconsin, LaCrosse Wisconsin

**Summary:** Techniques for taping pitted skin and adhered scars

**Emphasis of Presentation:** Scar management

---

Normal Skin consists of;  
Epidermis which is the outermost layer of the skin  
Dermis lies just deep to the epidermis.  
Underneath the skin is the subcutaneous tissue and muscle



Collagen is a protein that is mainly found in the second layer of your skin, called the dermis

When you suffer a cut, scrape, injury or surgical opening that goes beyond superficial layer (epidermis), and down to the second layer (dermis), exposure of the collagen occurs, which is then allowed to come to the skin's surface. Scars mainly consist of collagen.

Although it is possible to soften, or even get rid of an old scar, your best move is to stop scars from forming. It is easier to prevent a scar than to reduce it once it forms.

\* The key to preventing scars is to break up the collagen and not allow it to bond to your skin's top layer.

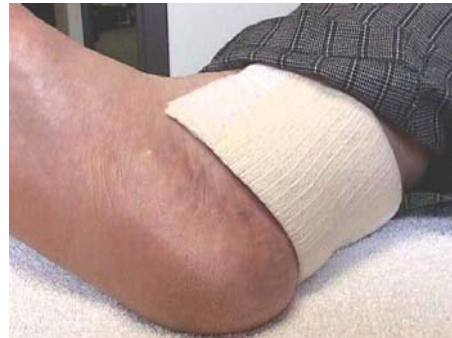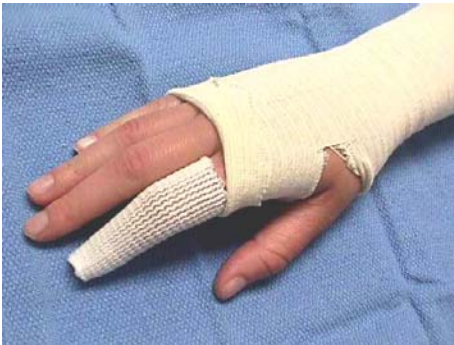## Preventing Scars



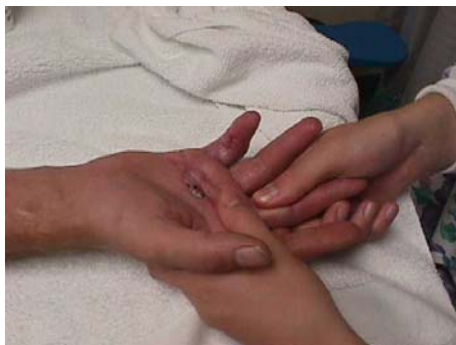Cover the wound so the wound stays moist to prevent scab formation.

(Scabbing presents a barrier to healing) \* The scab can create a barrier like ring and the wound has an increased depth that it has to go for healing.

\* Be very careful with moisture as too much moisture around the wound can cause maceration, which is skin break down.



Applying light pressure through compressive dressings or pads on the wound as it is healing keeps collagen from popping up above the skin when a wound is healing.



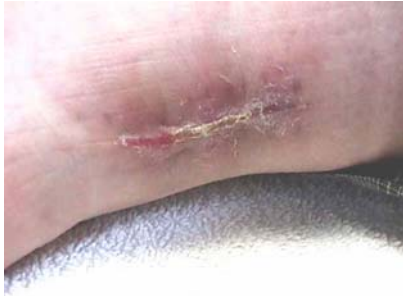Once the skin has grown over a wound, if a scar has formed, a gentle massage to the affected area can be provided. (Gently massage, with lotion, in a circular motion for 15-30 seconds a few times a day. Be sure not to rub across the skin. You want to gently move the underlying tissue).

## Reducing Scars After They Have Formed

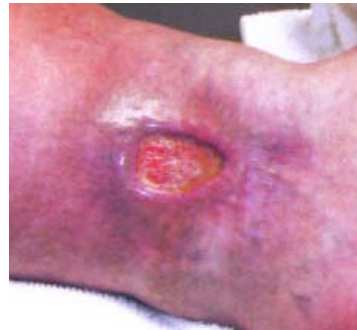

Scar tissue is like an iceberg. What you see is just a little part. The majority of the scar is under the surface. Make sure you feel around the visible scar for tight tissue.

A scar can take longer to heal if not managed. (Can have prolonged inflammatory stage until closure)



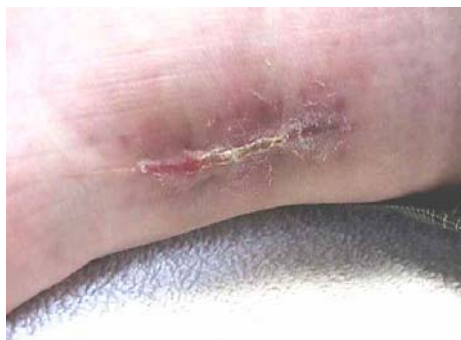Hypertrophic Scar- The collagen bulks up upon itself. The area appears raised. Note the redness still in the tissue.



Keloid Scar- The collagen goes beyond the original injury and affects healthy tissue. See the whorl-like and nodular formations

One wound → One Scar.

The purpose of scarring is closure of the wound; the collagen formation does not differentiate between tissues.



Scar tissue can adhere to tendons, ligaments, and the joint capsule, as well as connective tissue and skin. Unmanaged scarring can cause contractures. In severe cases, such as in burns, it can cause deformities.

## Kinesio Taping Scars

Caution : when Kinesio Taping Scars, do not apply Kinesio Tape on a scar until it is well healed. This would be when the scar is in its middle to later remodeling stage of healing. (Around 2-4 weeks after the wound is closed). Applying tape too early could cause extensive damage to the tissue. This could slow down wound healing. Be extra careful with patients with diabetes, venous insufficiency, and peripheral neuropathy. It is recommended that gentle manual techniques be provided as soon as the wound is closed prior to starting Kinesio Taping methods.

Scar taping assists in the softening of scar tissue and reducing adhesions and pitting. It helps to make the scar soft, flat and pliable and ultimately reduces the risk of contractures.

Low Load- Prolong Duration Stress on Scar Tissue, Helps to Soften and Remodel Scar Tissue. Applied stress to the scar helps to lay down collagen fibers in a more parallel pattern. Stress can be provided in the form of pressure or stretch.

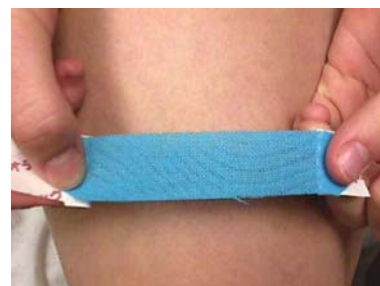Mechanical pressure with a corresponding stretch applied to a scar will eventually remodel the hypertrophic scar. If mechanical pressure is applied directly to the scar as soon as the development of hypertrophic scar is clinically evident, whorl like and nodular formations will change resulting in the reorientation of collagen fibers to elongated parallel patterns. Future contracture and hypertrophy is prevented or diminished. You can accelerate the natural healing process.



The knit of this sweater represents the connective tissue and fascia in the body. Notice how a slight pull affects the surrounding tissue and deeper tissue.

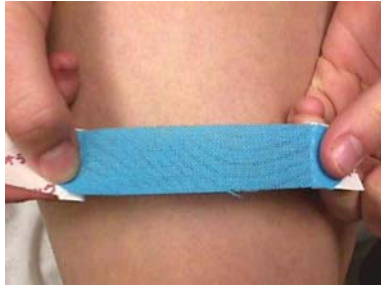Scar taping: Position the patient in maximal muscular and fascial/ skin elongation of the area of the scar.

Apply a base "I" tape with 25-50% stretch.  
Rub the tape after application to adhere the tape.



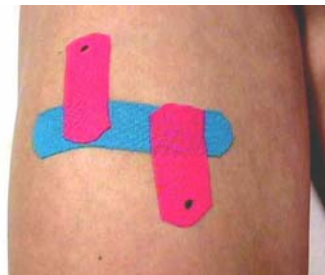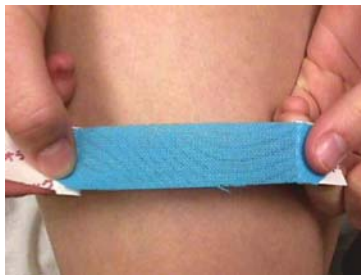Remember to start gently with scar tissue. You can gradually increase the tension to 50% only if the integrity of the skin can tolerate it. If the skin is too fragile, use only a gentle manual technique.

**Scar taping for pitting scars** such as after open reduction with external fixation or surgical scars is used to assist in the softening of scar tissue and reduction of pitting.



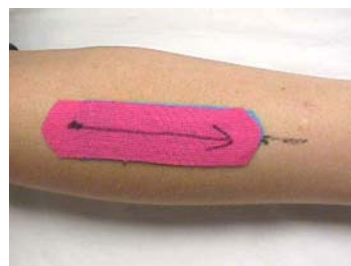
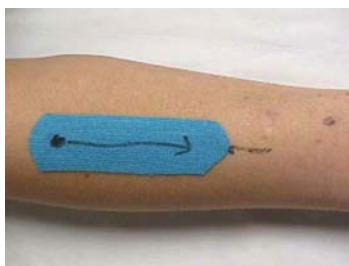
Position patient in maximal muscular, fascial/skin elongation of the area of the scar. Lay down an "I" tape with 25-50% stretch. Rub the tape after application to adhere the tape. Apply cross strip with 25-50% tension on tape to lift pitted area.

### Scar Taping with Directional Pull



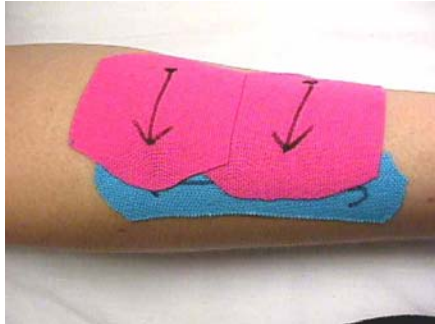
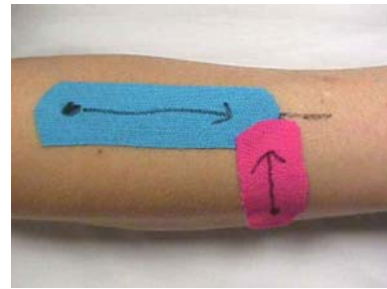
Scar taping with directional pull is used to assist in the softening of scar tissue and to reduce adhesions.

Position patient in maximal muscular, fascial/skin elongation of the area of the scar. Lay down an "I" tape with 25-50% stretch. Rub the tape after application to adhere the tape. Place cross strips with pulling the base strip in the desired direction with 25-5-% stretch in tape

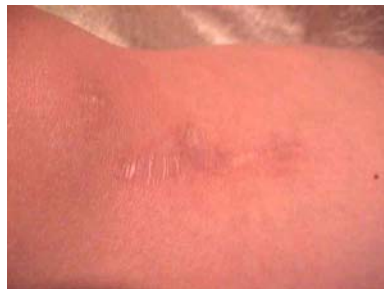

Adhered point on a long scar. Start anchor away from adhered point and then stretch the tape toward the scar with 25% tension then apply tape. Can add a second piece if needed.

Can add tape in 2 directions if needed. There are times when it is appropriate to apply a second tape at a different direction.  
Make sure to apply with 25% tension.

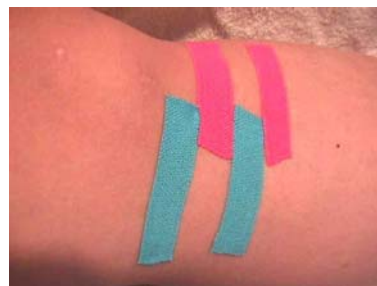

Directional side pull. At times the whole scar is adhered in one direction. A side taping may be appropriate with 25% tension.

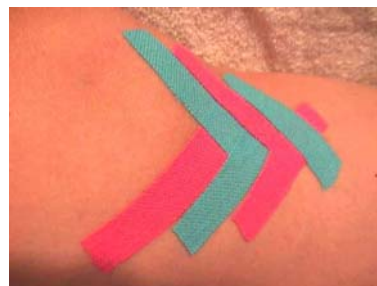

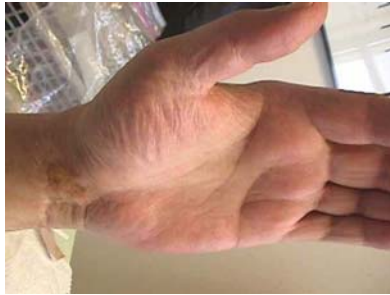Scar on knee after reconstructive surgery on the Anterior Cruciate Ligament.

Taping of scar induration to soften it. Cut 1/4 inch wide strips about 2 inches long. Start the anchor away from adhered point and then stretch the tape toward the scar with 25% tension, then apply tape. Alternate directions that the tape is applied.



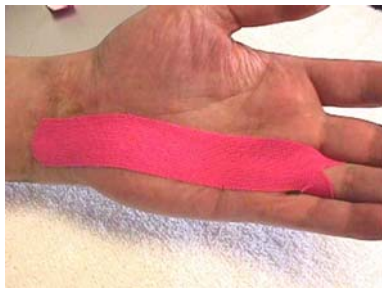Taping of scar induration with a directional pull. Taping of scar induration to soften it. Cut 1/4 inch wide strips about 2 inches long. Start the anchor away from adhered point at a 45° angle and stretch the tape toward the scar with 25% tension, then apply tape. Alternate directions that the tape is applied.





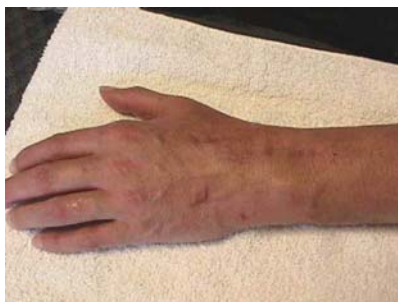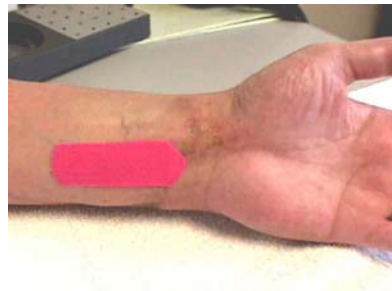Adhered **volar wrist scar** with flexor tendons adhered, reducing range of motion of fingers and wrists. Finger extension and finger flexion are limited.

Taping of volar scars (alternate applications).



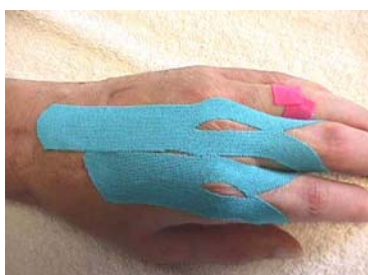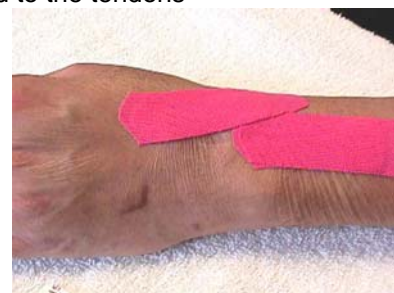This taping is used to encourage gliding motion of the scar in a *distal* direction. Attach the tape to the finger with 25-50% tension.

To encourage gliding motion of the scar in a *proximal* direction, attach the tape pulling proximal. Apply tape with 25-50% tension.



Adhered **dorsal wrist scar**. The scar tissue adhered to the tendons limits finger extension and flexion

Taping of the dorsal adhered scar. This taping is to encourage gliding motion of the scar in the *proximal* direction; attach the tape with 25-50% tension.



To encourage gliding motion of the scar in a *distal* direction, attach the tape to the finger with 25-50% tension.

